



## Case Report

## Traumatic dislocation of bilateral hips and ankles

Min-Shiu Huang<sup>a</sup>, Horng-Chaung Hsu<sup>a</sup>, Yi-Chin Fong<sup>a</sup>, Chia-Hao Chang<sup>b,\*</sup><sup>a</sup> Department of Orthopaedic Surgery, China Medical University Hospital, Taichung, Taiwan<sup>b</sup> Department of Orthopaedic Surgery, Chang-Hwa Hospital, Department of Health, Chang-Hwa, Taiwan

## A B S T R A C T

## Keywords:

ankle dislocation  
bilateral hips and ankles  
hip dislocation

Bilateral traumatic hip dislocation is rare, and pure ankle dislocation without bony fracture is also rare. We present a patient who sustained bilateral hip and bilateral ankle dislocations without associated fracture after a fall from a significant height. Management consisted of immediate closed reduction of bilateral hips and bilateral ankles under conscious sedation in the emergency department, followed by immobilization of the ankles with short leg splints. After 2 weeks of bed rest with skin traction, the patient was initially mobilized in a wheelchair. He was allowed partial weight bearing after 4 weeks. Clinical and radiographic follow-up continued for 2 years after the accident. The patient reported complete disappearance of pain in hips and ankles. Good range of motion of the hips and ankles was also noted. There was no radiographic evidence of avascular necrosis, osteoarthritis, or calcification at 2-year follow-up.

Copyright © 2010, Taiwan Orthopaedic Association. Published by Elsevier Taiwan LLC. All rights reserved.

## 1. Introduction

Traumatic dislocations of the hip comprise about 2%–5% of all dislocations.<sup>1</sup> Bilateral traumatic hip dislocation is very uncommon, and only 50 cases have been reported.<sup>2</sup> Epstein<sup>3</sup> and Speed<sup>4</sup> estimated that the incidence of bilateral hip dislocation was about 1.25% of all hip dislocations or about 0.025%–0.05% of all dislocations.

Pure dislocation of the ankle without bony fracture is an extremely rare injury. The rarity is due to the mechanical efficacy of the ankle mortise and resistance of the ankle ligaments being greater than that of bone.

Herein, we report a case of bilateral traumatic posterior hip dislocation and bilateral pure anterior ankle dislocation without bone injury. To our knowledge, simultaneous dislocation of four major joints has never been reported.

## 2. Case report

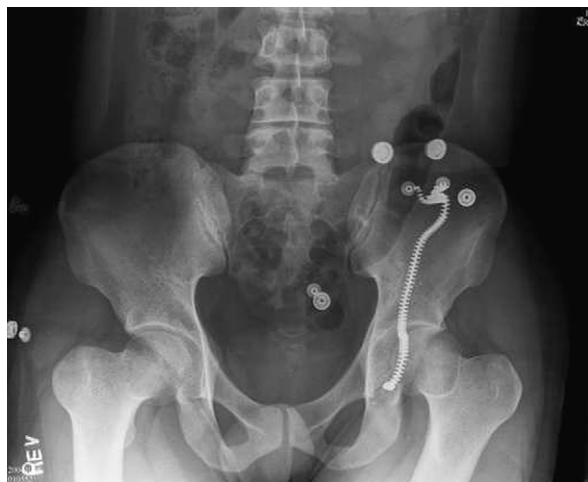A 30-year-old man (height, 170 cm; mass, 70 kg) presented to the emergency department (ED) with bilateral hip and bilateral ankle dislocations after a fall from a significant height. The patient initially fell from a height of 20 m after jumping from the roof of an eight-story building and landing on the roof of an adjacent three-story building while trying to evade capture by police. Severe pain of bilateral hips, which were fixed in flexion, was noted at that time. The patient then fell to the ground from the three-story building (6 m). The impact of the second fall was absorbed by both heels.

On arrival, the patient was conscious and had a Glasgow Coma Scale score of 15. The vital signs were stable. Sonography revealed no signs of internal bleeding. The hips were in an adducted, flexed, and internally rotated position. Bilateral ankles were fixed in plantar flexion. No neurovascular deficit was found.

An anterior-posterior (AP) pelvic X-ray study showed a displaced left hip joint with loss of congruity. Images of the right hip demonstrated that the congruity between the femoral head and roof of the acetabulum was well

\* Corresponding author. Department of Orthopaedic Surgery, Chang-Hwa Hospital, No. 80, Sec. 2, Zhongzheng Rd., Puxin Township, Changhua 513, Taiwan. Tel.: +886 4 2205 2121x5052; fax: +886 4 2203 8316.

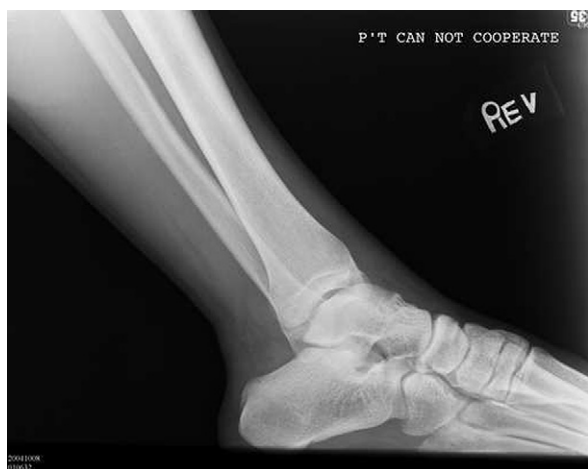E-mail address: [icubook1a1@yahoo.com.tw](mailto:icubook1a1@yahoo.com.tw) (C.-H. Chang).



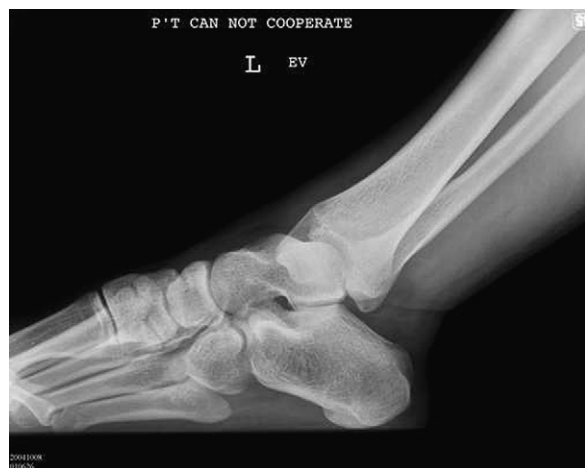**Fig. 1.** Anterior-posterior pelvic X-ray. Left femoral head is clearly displaced, and loss of congruity with acetabulum is visible. Incongruence was not apparent at the right hip joint.

maintained (Fig. 1). Pelvic computed tomography (CT) scan revealed posterior dislocation of bilateral hips with no evidence of fracture (Fig. 2). The patient was uncooperative; therefore, only a lateral view X-ray image of the ankles could be obtained. The image showed anterior dislocation of both ankles (Figs. 3 and 4).

Conscious sedation with good muscle relaxation was achieved in the ED with 100-mg propofol. Closed reduction of the right ankle was performed first. Longitudinal traction with the right knee flexed was applied. A successful reduction was accomplished without difficulty by applying a posteriorly directed force to the right foot with the ankle stabilized. The left ankle was reduced in a similar fashion (Fig. 5). Then, both hips were reduced by closed manipulation. After reduction, hip stability was excellent, leg lengths were normal, and there was no evidence of postreduction neurovascular compromise (Fig. 6). We applied short leg splints to immobilize the ankles for 30 days. After 2 weeks of



**Fig. 2.** Lateral view of the right ankle shows dislocation of the ankle.

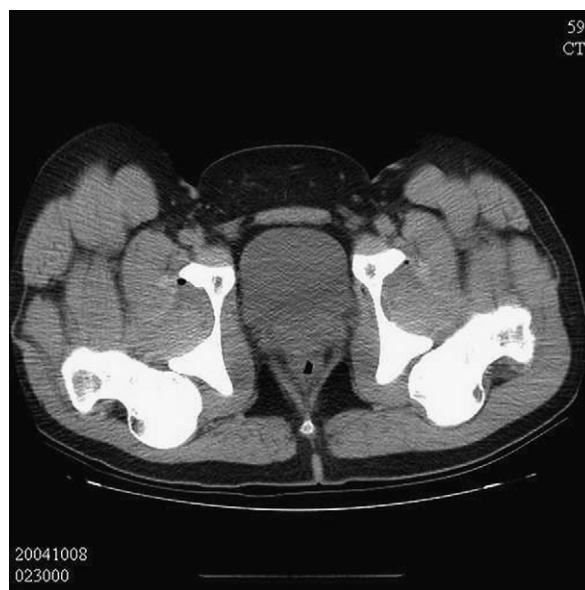


**Fig. 3.** Lateral view of the left ankle shows dislocation of the ankle.

skin traction, the hips were allowed to move under supervision. The patient was initially mobilized in a wheelchair, and partial weight bearing was allowed at the fourth week. Indomethacin was not prescribed. At 24-month follow-up, the joints appeared normal on radiographs, and there were no signs of avascular necrosis, osteoarthritis, or calcification (Fig. 7).

### 3. Discussion

Bilateral symmetric (anterior or posterior) traumatic hip dislocation is a rare event, and simultaneous asymmetrical (anterior and posterior) traumatic dislocation of both hips is even more unusual. Brav<sup>5</sup> reported six cases of bilateral dislocations: three asymmetric (anterior and posterior),



**Fig. 4.** Pelvic computed tomography shows bilateral hip posterior dislocation without associated fracture.

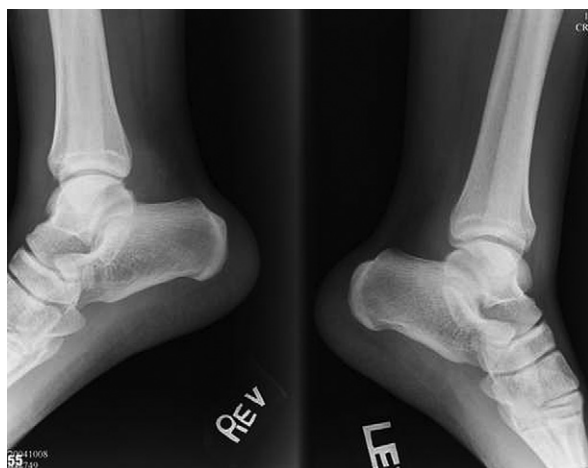

Fig. 5. Lateral view of right and left ankles after reduction.

two bilateral posterior, and one bilateral anterior. Honner and Taylor<sup>6</sup> reported a case of bilateral traumatic anterior hip dislocation and found there are only 10 prior case reports in the English language literature. Four case reports of bilateral asymmetric traumatic hip dislocation have been located in the review by MEDLINE from January 1966 to January 2010.<sup>2,7–9</sup>

The typical mechanism of injury is thought to be sudden deceleration, which usually affects front seat unrestrained passengers in a vehicle, causing injuries to the lower limbs. Depending on the position of the legs at the moment of the crash, the impact may cause anterior or posterior dislocation.<sup>1</sup> Posterior hip dislocation most commonly occurs as a result of a “dashboard injury” and is associated with internal rotation and adduction on the affected leg. Letournel and Judet<sup>10</sup> used vector analysis to explain that the more flexion and adduction the hip is when a longitudinal force is applied through the femur, the more likely a pure dislocation will occur.

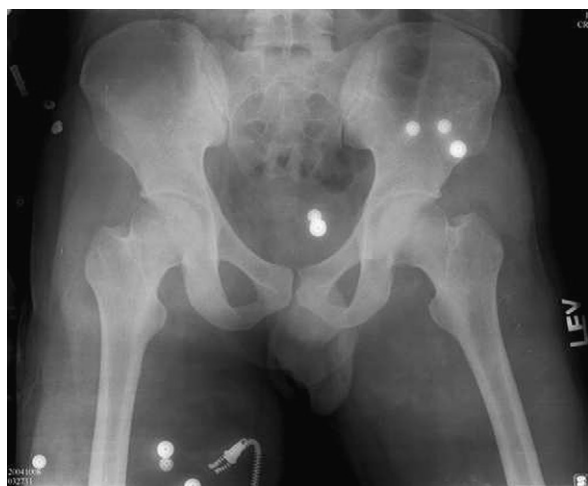

Fig. 6. Anterior-posterior pelvic X-ray (after reduction) shows anatomic reduction of both hips.

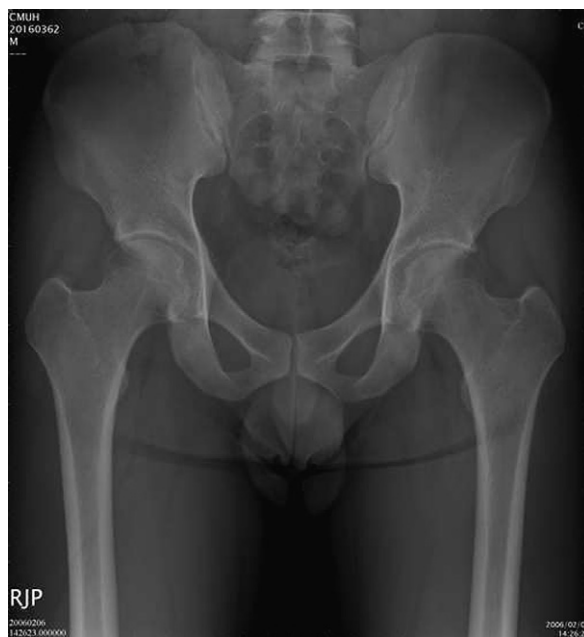

Fig. 7. After 24 months of follow-up, no avascular necrosis of the femoral heads or obvious traumatic arthritis is noted.

Routine AP pelvis radiographs will confirm the diagnosis of a simultaneous bilateral traumatic hip dislocation, but this injury can be missed in as many as 50% of cases.<sup>1</sup> The examination of the position of the limbs and the reconstruction of the mechanism of injury are thus important. Significant flexion of the hip can diminish the classic radiographic findings of hip dislocation.<sup>11</sup> In our patient, the ankles were fixed in plantar flexion and resulted in more flexion of the hips when the patient was in a supine position. The flexed hips made it difficult to interpret the hip dislocation on the initial plain film. So, in this case, instead of doing closed reduction immediately, we arranged for a CT scan first in order to confirm the bilateral hip dislocation and for additional evaluation.

Traumatic hip dislocation should be reduced as soon as possible to prevent complications such as osteonecrosis of the femoral head, traumatic arthritis, joint instability, nerve injury, and periarticular calcification of soft tissues.<sup>12</sup> The threshold for high risk of complications has been reported to be 6 hours.<sup>4</sup> General anesthesia may be necessary to achieve adequate muscle relaxation for closed reduction when there is no associated fracture although the procedure can generally be performed under conscious sedation in the ED. Open reduction is often needed in patients with radiographic evidence of fracture, in patients with ineffective closed reduction, or if the sciatic nerve must be explored.<sup>1</sup> Kirkos et al<sup>13</sup> reported on an unusual case of anterior traumatic hip dislocation in which the femur had a 90° anterior rotation while the femoral head was exactly at the same level as when normal. They named this type of dislocation an “intermediate” or “inguinal” dislocation. Their patient underwent open reduction, and the femoral head was found trapped in the capsule and muscle. Maqsood and Walker<sup>14</sup> reported on a new technique for

reduction in a case of bilateral dislocation of the hips with ipsilateral femoral shaft fracture. They used a Schanz screw for reduction without opening the joint or fracture site. In the past, it was recommended that reduction by skeletal or skin traction be maintained for at least 6 weeks; however, it is now generally agreed upon that skeletal or skin traction be maintained for only a few days.<sup>15</sup> Follow-up radiographs are recommended at 3-month intervals for at least 2 years to check for the development of avascular necrosis.

Pure dislocation of the ankle, or dislocation not accompanied by fracture of the malleolus of the posterior border of the tibia, is an extremely rare injury.<sup>16</sup> D'Anca<sup>17</sup> explained that the rarity of that injury was attributable to the mechanical efficiency of the mortise and the resistance of the ankle ligaments being greater than that of bone. Fahey and Murphy<sup>18</sup> classified talotibial dislocations into five types based on the direction of the dislocation: anterior, posterior, medial, lateral, or superior combined. Total superior displacement of the talus is rare. Because this is an uncommon injury, there is no standard treatment protocol. Most authors recommend closed reduction, cast immobilization, and several weeks of nonweight bearing in the treatment of both open and closed talotibial dislocations. The repair of disrupted ligamentous structures is controversial. Colville et al.<sup>19</sup> advocate that repair of lateral, but not medial, ligaments should be performed in open injuries at the time of initial debridement. Mestdagh and Larzul<sup>20</sup> reported that surgical repair of torn ligaments in two cases did not appear to improve outcome. Wroble et al.<sup>21</sup> however, stated that ligamentous repair does not affect function, and, therefore, they do not recommend the procedure. Fahey and Murphy<sup>18</sup> and Kelly and Peterson<sup>22</sup> reported syndesmotic disruption with these injuries, but neither group recommends any treatment beyond reduction and cast immobilization.

Pure dislocation of the ankle has a good long-term prognosis. Immediate reduction followed by immobilization and adequate cutaneous covering lead to a positive result in most cases.<sup>23</sup>

#### 4. Conclusion

We report a case of bilateral traumatic posterior hip dislocation and bilateral pure anterior ankle dislocation without bone injury. In patients with high-energy trauma, especially trauma resulting from a significant height, the hip and ankle joints must be evaluated carefully. As the

incidence of complications increases with the time to reduction, immediate closed reduction will lead to good prognosis.

#### References

1. P.C. Shukla, S.E. Cooke, C.V. Pollack, J.C. Kolb, Simultaneous asymmetric bilateral traumatic hip dislocation, *Ann Emerg Med* 22 (1993) 1768–1771.
2. T. Ashraf, A.A. Iraqi, Bilateral anterior and posterior traumatic hip dislocation, *J Orthop Trauma* 15 (2001) 367–368.
3. H.C. Epstein, Traumatic dislocations of hip, *Clin Orthop Relat Res* (92) (1973) 116–142.
4. K. Speed, Simultaneous bilateral traumatic dislocation of the hip, *Am J Surg* 85 (1953) 292–297.
5. C.E.A. Brav, Traumatic dislocation of the hip—army experience and results over a twelve-year period, *J Bone Joint Surg* 44 (1962) 1115–1134.
6. S. Honner, S.M. Taylor, Bilateral anterior traumatic hip dislocation, *J Emerg Med* (2009) [e-pub ahead of print].
7. M.E. Gittins, L.W. Serif, Bilateral traumatic anterior/posterior dislocations of the hip joints: case report, *J Trauma* 31 (1991) 1689–1692.
8. F. Lam, J. Walczak, A. Franklin, Traumatic asymmetrical bilateral hip dislocation in an adult, *Emerg Med J* 18 (2001) 506–507.
9. M. López-Sánchez, N. Kovacs-Kovacs, Bilateral asymmetric traumatic hip dislocation in an adult, *J Emerg Med* 31 (2006) 429–431.
10. E. Letournel, R. Judet, Fractures of the acetabulum, in: *Mechanics of Acetabular Fracture*. Springer, Berlin, 1993, pp. 23–28.
11. R.W. Bucholz, J.D. Heckman, Rockwood and Green's Fractures in Adults, Chapter 37. Hip Dislocations and Fractures of the Femoral Head. Lippincott Williams & Wilkins, Boston, 2001.
12. H.C. Epstein, Posterior fracture-dislocation of the hip: long term follow up, *J Bone Joint Surg Br* 67 (1985) 232–236.
13. J.M. Kirkos, A.M. Kyriakides, M.J. Kyrkos, Unusual displacement of the femoral head in anterior traumatic dislocation of the hip. A case report, *Chir Organi Mov* 86 (2001) 69–72.
14. M. Maqsood, A.P. Walker, Asymmetrical bilateral traumatic hip dislocation with ipsilateral fracture of the femoral shaft, *Injury* 27 (1996) 521–522.
15. I. Dudkiewicz, M. Salai, S. Horowitz, A. Chechik, Bilateral asymmetric traumatic dislocation of the hip joints, *J Trauma* 49 (2000) 336–338.
16. B. Leitner, The mechanism of total dislocation of the talus, *J Bone Joint Surg Am* 37 (1955) 89–95.
17. A.F. D'Anca, Lateral rotatory dislocation of the ankle without fracture, *J Bone Joint Surg Am* 52 (1970) 1643–1646.
18. J.J. Fahey, J.L. Murphy, Dislocations and fractures of the talus, *Surg Clin North Am* 45 (1965) 79–102.
19. M. Colville, J. Colville, A. Manoli, Posteromedial dislocation of the ankle without fracture, *J Bone Joint Surg Am* 69 (1987) 706–710.
20. H. Mestdagh, M. Larzul, Luxation isolee de la tibio-tarsienne. A propos de 4 cas, *Med Chir Pied* 1 (1984) 107–112 [in French].
21. R. Wroble, J. Napola, T. Malvitz, Ankle dislocation without fracture, *Foot Ankle* 9 (1988) 64–74.
22. P.J. Kelly, L.F.A. Peterson, Compound dislocation of the ankle without fracture, *Am J Surg* 103 (1962) 170–172.
23. J.S. Toohey, R.A. Worsing, A long-term follow-up study of tibiotalar dislocations without associated fractures, *Clin Orthop Relat Res* 239 (1989) 207–210.